

## Review Article

## Anesthesia for Zenker's Diverticulectomy

Basem Abdelmalak<sup>1</sup>, and Ashish Khanna<sup>1,2</sup>

## ABSTRACT

**Aim of review:** The anatomic location of Zenker's diverticulum comes along with an inherent risk of aspiration at any given stage of surgery. This risk contributes greatly to the challenge in the anesthetic approach to these patients.

**Methods:** We have reviewed and summarized the available literature on surgical techniques, complications and the anesthetic management for Zenker's diverticulum in the past decades. Where needed, we mentioned practical clinical pearls from the extensive personal experience of the authors, and their colleagues in the field of anesthesia for otolaryngologic surgery. We also used radiologic images, and artist rendered cartoons to illustrate discussed principles.

**Recent findings:** Zenker's diverticulum is associated with a risk for aspiration. For open surgery under general anesthesia, consider either a smooth expedited induction in a 10-30 degree head up tilt or induction following an awake intubation. Consider not using oral antacid premedication, nor applying cricoid pressure if the neck of the pouch is above the cricoid ring or inserting a nasogastric tube blindly. Regional anesthesia techniques utilizing superficial and deep cervical plexus blockade can be an alternative. They have the advantages of an awake and responsive patient with preserved reflexes. However, they are considered technically difficult by some, with a variable failure rate and patient acceptability.

**Summary:** We have discussed the advances in the surgical techniques to treat Zenker's diverticulum. However, unfortunately, the anesthesia literature has not adequately and directly addressed and/or discussed the anesthetic challenges for Zenker's diverticulectomy in the recent years. Thus, the timely significance of this review where we applied modern concepts and understanding to the management of Zenker's diverticulum. It is our hope that this review increase awareness among current and future clinicians to advance care for Zenker's diverticulum patients.

From <sup>1</sup>Departments of General Anesthesiology and Outcomes Research, <sup>2</sup>Surgical ICU & Center for Critical Care, Anesthesiology Institute, Cleveland Clinic and Cleveland Clinic Lerner College of Medicine of Case Western Reserve University, Cleveland, OH, USA.

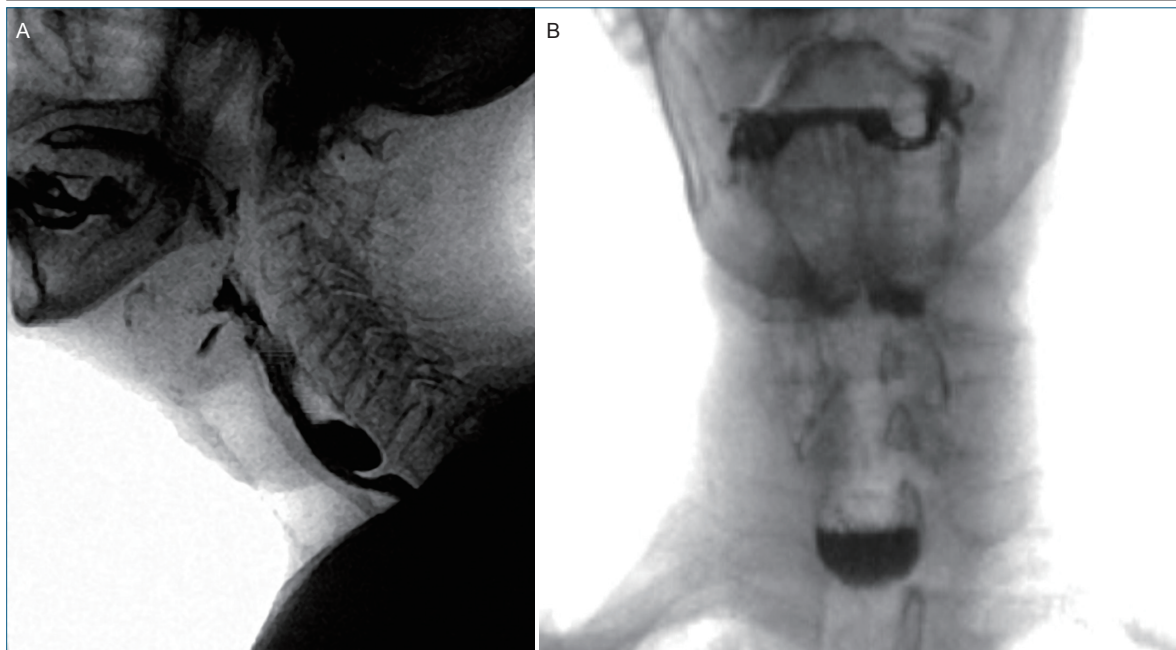
**Correspondence** to Dr. Basem Abdelmalak at [abdelm@ccf.org](mailto:abdelm@ccf.org).

**Citation:** Basem Abdelmalak, Ashish Khanna. Anesthesia for Zenker's diverticulectomy. *J Anesth Perioper Med* 2017; 1: 17-22.

Zenker diverticulum is a herniation of pharyngeal mucosa through the posterior wall of hypopharynx as first described by Zenker and Von Ziemssen in 1874 (1). It is an acquired disorder encountered in the 6<sup>th</sup> to 9<sup>th</sup> decades of life with a reported incidence of approximately 1 in 800 upper gastrointestinal barium studies (2).

An older patient population comes with its own set of anesthetic and perioperative challenges. In addition, the lo-

cation of this anatomical aberrancy comes along with the inherent risks of aspiration at any given stage of surgery (pre, intra and/or postoperative periods). All of these contribute to the challenge in the anesthetic approach to these patients. This review provides the reader with a step by step approach to perioperative management of these patients and a detailed understanding of the anesthetic considerations for this unique surgical procedure.



**Figure 1. Views of a Modified Barium Swallow Study Showing Zenker's Diverticulum** (Reprinted with permission from the Cleveland Clinic Arts Department, all rights reserved©2017).  
 A. A lateral view; B. An anteroposterior view, showing an air-fluid level within the pouch.

### Surgical Anatomy

This defect occurs most commonly through the posterior pharyngeal wall, located below the inferior constrictor and above the cricopharyngeus muscle. This is believed to be a consequence of spasm or dysfunction of the cricopharyngeus muscle (3).

### Clinical Presentation

The patient presents invariably to the outpatient clinic with dysphagia, globus, halitosis, coughing and a characteristic regurgitation of undigested food (more when lying down). Imaging may show a widening of the upper mediastinum. X-rays of the neck may disclose a collection of air anterior to the fifth and sixth cervical vertebrae.

A barium swallow test is often used to confirm the diagnosis. Typically, it reveals a pouch in the proximal posterior esophagus, with a neck usually located slightly above the level of the cricoid ring (Figure 1). Moreover, an endoscopic examination allows for visualization of the pouch albeit, often filled with undigested food; hence, the commonly encountered regurgitation of undigested food as discussed above (4-6).

### Treatment Options

Surgical treatment (either open or endoscopic) aims at dividing the cricopharyngeus muscle and resecting the pouch.

#### Open Surgery

##### *Transcervical Surgical Approach*

The diverticulum is exposed through a lateral neck incision. The pouch may be resected (diverticulectomy) or tacked superiorly to the prevertebral fascia (diverticulopexy). These procedures are usually done in conjunction with a cricopharyngeal myotomy (a procedure to surgically weaken the cricopharyngeus muscle and prevent a recurrence of the pathology).

#### Endoscopic (7, 8)

This approach differs from open surgery in that no skin incision is required, and requires a shorter hospital stay.

##### *Dohlman Procedure*

The diverticulum is exposed with a bivalved (two-blade) endoscope with one blade in the pouch and the other blade in the cervical esophagus. Under direct visualization, the common

wall between the pouch and the esophagus is ablated (usually with the carbon dioxide laser).

#### *Endoscopic Staple Diverticulotomy*

The redundant hypopharyngeal mucosa is not removed and the cricopharyngeus muscle is partially divided. A bivalved endoscope is placed through the mouth to expose the cricopharyngeus muscle. Similar to the Dohlman procedure, one blade is placed in the Zenker's diverticulum and the other in the cervical esophagus. The common wall separating the diverticulum from the esophagus is reduced with an endoscopic stapler, which prevents food material from collecting within the diverticulum.

For the purposes of this review, we will focus on the anesthetic management of an open surgical procedure since the endoscopic procedure is generally done under moderate (conscious) sedation, on an outpatient basis.

### Anesthetic Management

#### Preoperative

An accurate and thorough preoperative screening for coronary artery disease is imperative since this is a disease usually confined to the geriatric age group. This is especially true in the face of symptomology for coronary ischemia, which may necessitate fixing the underlying lesion before operating on the diverticulum.

**Aspiration:** Compared to the commonly known and described gastric acid aspiration, the pouch content is alkaline, so aspiration of such content does not result in acid related aspiration pneumonitis (6). Nonetheless, the condition is not uncommonly associated with recurrent aspiration pneumonitis or even lung abscess since oral flora predominate the aspirated material (9).

**Malnutrition:** This is a common finding in these patients and, at least theoretically, may negatively impact postoperative surgical outcomes. This may warrant optimization prior to surgery.

As a general principle, this is an elective procedure. This means that all potentially reversible preoperative problems should be evaluated and addressed.

**Pre-operative fasting:** As for any other procedures; pre-operative fasting is recommended. It

is important to realize that a fasting period of more than the usual 6 hours prior to initiation of induction does not guarantee an empty pouch. Oral premedication should be avoided because premedicants may lodge in the pouch and may be aspirated to the lung. The use of antacids or H<sub>2</sub> blockers is of little to no value because the contents of the pouch have an alkaline pH to start with (4, 6, 10).

### Operating Room Safety

If laser is to be used, the adoption of the universal protocol for anesthesia safety during laser procedures is warranted. This may include the use of laser safe tube and precautions to prevent airway fires, appropriate protective goggles for operating room (OR) staff and patients, and hanging laser signs on OR doors.

### General Anesthesia Technique

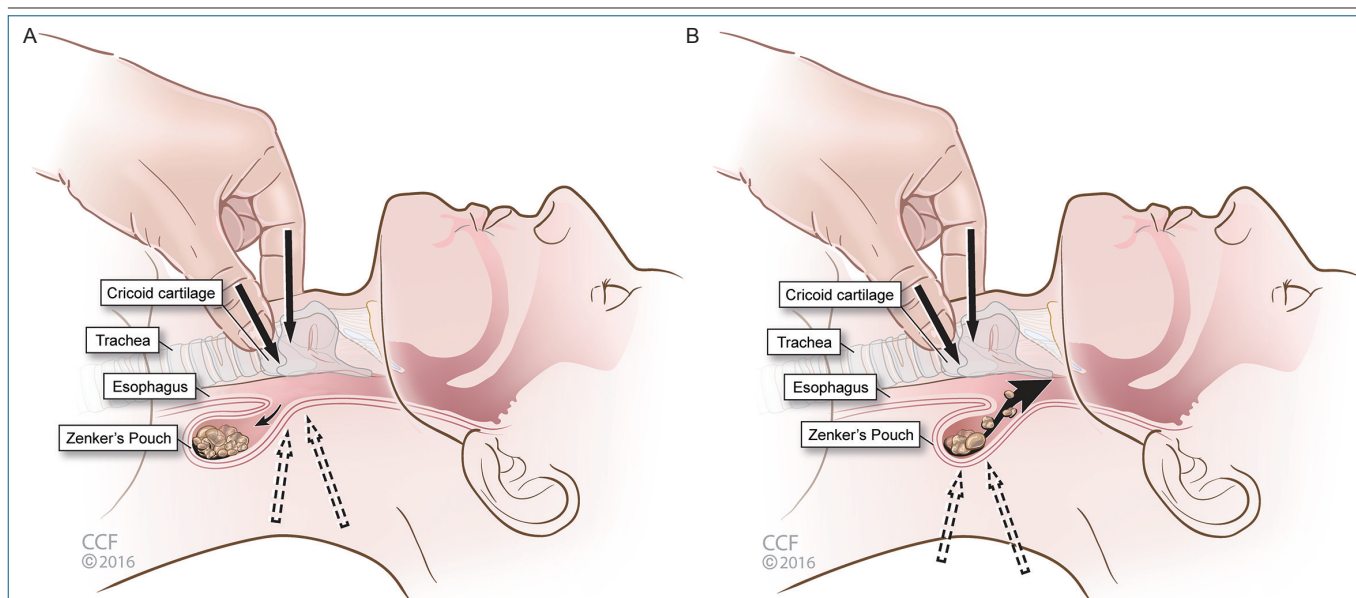
#### Induction of Anesthesia

Safe induction of anesthesia, minimizing the risks of aspiration is a key element to the anesthetic technique. External pressure (4), may be used to empty this pouch preoperatively. However, this may contribute to iatrogenic regurgitation and subsequent aspiration and is of unproven benefit (4). Positioning the patient in head-up tilt at the time of induction of anesthesia (6), has been used to help prevent aspiration as well. Various options for securing the airway are discussed below:

#### Awake Intubation

Awake intubation using a flexible fiberoptic bronchoscope or other suitable airway devices is a reasonable option when there is a large pouch extending to the mediastinum and/or an orifice above the cricoid ring as seen on a barium swallow (9). This is helpful since maintaining airway reflexes provides a natural protection against the risk of aspiration of regurgitating pouch content.

When performing an awake intubation, adequate topicalization of the airway is essential. However, an effort should be made to focus topicalization to the supraglottic region and minimize local anesthetic application to the trachea



**Figure 2. Cartoon Showing the Consequences of Cricoid Pressure Application in Zenker's Diverticulum in Two Different Scenarios Depending on the Anatomical Size and Location of the Pouch** (Reprinted with permission from the Cleveland Clinic Arts Department, all rights reserved©2017).

A. When the neck of the pouch is posterior to the cricoid cartilage, it gets occluded resulting in potential benefit against regurgitation and aspiration of the pouch contents. B. When the body of the pouch is posterior to the cricoid cartilage and the neck is above. The pouch contents may be regurgitated, and potentially aspirated.

(i.e. avoid transtracheal block) to maintain robust protective airway reflexes.

Many clinicians believe that it takes multiples of the usual local anesthetic dose used to topicalize the trachea to abolish such protective reflexes. Moreover, another concern is that transtracheal injection of local anesthetics is known to trigger coughing, which along with straining, could theoretically induce regurgitation of pouch content and potential aspiration (11).

### Rapid Sequence Induction

The use of a rapid sequence induction (RSI) with or without cricoid pressure has been debated for many years in the prevention of aspiration in full stomach scenarios during the induction of general anesthesia (12, 13). The size of the pouch and the anatomical position of the orifice of the pouch are some of the factors to be considered while considering applying cricoid pressure. Application of cricoid pressure has been only recommended if the neck of the pouch is below the cricoid cartilage (Figure 2). Figure 2A shows the potential benefit of application of cricoid pressure if the pouch is large, extending down into the mediastinum (with its orifice at the level of

the cricoid cartilage and neck below the cricoid), it is possible that cricoid pressure will obliterate the opening and protect against regurgitation. In other circumstances though, the neck of the pouch is above the cricopharyngeus muscle, and thus the cricoid ring is below the neck of the diverticulum (6). As seen in Figure 2B, this makes the application of cricoid pressure potentially more harmful than helpful by squeezing the pouch, which would result in increasing pressure within the pouch and inducing regurgitation of its content into the hypopharynx, increasing the likelihood of pulmonary aspiration. Therefore, it would be helpful to review preoperative imaging with the surgical team to determine the exact location of the pouch. Thus, the application of cricoid pressure in some cases may increase rather than decrease the risk of regurgitation (and potentially aspiration) in patients with Zenker's diverticulum (6, 14).

A common sense strategy would be a smooth expedited induction with no coughing or straining (6, 11), and an additional 30 degree head upward tilt with induction may be a very helpful and safer choice than applying a cricoid pressure, that is also known to potentially make ven-

tilation and intubation more difficult. After adequate pre-oxygenation, an intravenous hypnotic supplemented with opioids and/or lidocaine, followed immediately by adequate dose of non-depolarizing muscle relaxant with or without mask ventilation with O<sub>2</sub>, usually results in a smooth induction.

After intubation, the cuff of the single-lumen tube must be promptly inflated to provide adequate sealing of the airway. The use of succinylcholine which is commonly used for a traditional rapid sequence induction has been questioned here because if used alone, and not preceded by a small dose of a non-depolarizing muscle relaxant, it could induce muscle fasciculations this may cause compression of the pouch and deleterious consequences as discussed above (11).

### Intraoperative

While regurgitation and aspiration are almost always considered during the induction of anesthesia and during intubation, it could still happen even after successful intubation (4). This is thought to be due to the seepage of fluid around the single-lumen tube cuff during surgical manipulation. Intraoperatively, it has been suggested that a moist gauze pack placed around the endotracheal tube may add another protective mechanism and prevent aspiration during surgery (4).

### Perforation of the Diverticulum

Diverticulum perforation may occur during a difficult intubation, with blind attempts at intubation of the trachea. It could also occur during blind placement of a nasogastric tube. A recommended technique is to insert the nasogastric tube under surgical guidance once adequate access to the pouch has been established.

Other intraoperative concerns include blood loss and air embolism that may occur if major vessels are inadvertently severed. Moreover, with retraction of the carotid sheath the baroreceptors may initiate tachyarrhythmia or bradyarrhythmias (4).

### Regional Anesthesia Technique

Alternatively, the procedure can be performed

under regional anesthesia using deep and superficial cervical plexus blocks (15). Regional anesthesia can decrease the risk of aspiration, by preserving protective airway reflexes. An awake, alert patient is able to cooperate with the surgeon and to swallow on command, allowing the surgeon to view the pathology in action. After repair of the diverticulum with the incision still open, the patient is fed a small spoonful of gelatin so as to test the adequacy of correction under direct vision (16). Nevertheless this technique has not gained wide spread utilization and the majority of Zenker's diverticulum surgeries are done under general anesthesia. This is primarily because the desired regional blocks are considered technically difficult by some with a variable failure rate and, more importantly, patients' acceptability (or lack thereof) and uncooperativeness.

### Postoperative Management

As it is the case in other neck surgery, a smooth extubation with an awake patient adequately reversed from muscle paralysis is desirable to avoid the risks of neck hematoma compromising the airway. While there are different approaches to accomplish this goal, the authors utilize a narcotic loading technique in which an adequate dose of long acting narcotic, hydromorphone for example is given with incision (0.01- 0.02 mg/kg) in 0.4 mg increments 5 minutes apart as blood pressure tolerates, allows for a smooth wake up, without much cough or strain. The post anesthesia care unit (PACU) orders should include nursing with the head elevated. This is particularly important in patients with Zenker's undergoing another surgery in which the pouch has not been excised. Most of the surgeons will have the nasogastric tube on gravity drainage for a prolonged period of time and oral feeding will be initiated only after the closure of the surgical anastomosis has been confirmed.

### Complications

In addition to what is discussed above, complications from this surgery can include — fistula formation, perforation, recurrent laryngeal nerve injury, neck hematoma, infection, aspiration pneumonitis, and in very rare cases mortality.



## Patients with Zenker's Diverticulum for Other Surgical Procedures

The presence of a Zenker's diverticulum in a patient having other elective surgery should not be overlooked because this will increase the risk of regurgitation and pulmonary aspiration during the intraoperative and the postoperative periods. It might be wise to consider excising the pouch before any other elective procedure if possible to prevent silent aspiration.

## Conclusions

Anesthesia for Zenker's diverticulectomy is a

complex anesthetic and airway challenge. We recommend a thorough preoperative evaluation that includes detailed cardiovascular and nutritional status evaluation and optimization, preoperative fasting, and expedited induction in a 10-30 degree head up tilt, or induction of anesthesia following an awake intubation. We do not recommend using oral antacid premedication, applying cricoid pressure if the neck of the pouch is above the cricoid ring or inserting an oro/nasogastric tube blindly. Regional anesthesia techniques utilizing superficial and deep cervical plexus blockade can be used as an alternative anesthetic technique.

Support: Supported only by internal funds.

The authors have no conflicts of interest for this work to declare.

## References

- Zenker FA, von Ziemssen H. Krankheiten des Oesophagus. In: Von Ziemssen H, ed. *Handbuch der Speciellen Pathologie und Therapie*. Volume 7 (Suppl). Leipzig: FC Vogel, 1874:1-87.
- Dorsey JM, Randolph DA. Long-term evaluation of pharyngo-esophageal diverticulectomy. *Ann Surg* 1971; 173:680-5.
- Last RJ, ed. *The pharynx, anatomy, regional and applied*. London: Churchill Livingstone, 1973.
- Thiagarajah S, Lear E, Keh M. Anesthetic implications of Zenker's diverticulum. *Anesth Analg* 1990; 70:109-11.
- Kaplan M DE, Blevins N, Jackler R, Hwang P, Sunder S, Most S, Fee Jr. W, et al. Zenker's diverticulectomy. In: Richard A. Jaffe, Stanley I. Samuels, eds. *Anesthesiologist's manual of surgical procedures*. 4th ed. Philadelphia, PA: Lippincott Williams & Wilkins, 2009:191-3.
- Aouad MT, Berzina CE, Baraka AS. Aspiration pneumonia after anesthesia in a patient with a Zenker diverticulum. *Anesthesiology* 2000;92:1837-9.
- Little RE, Bock JM. Pharyngoesophageal diverticuli: diagnosis, incidence and management. *Curr Opin Otolaryngol Head Neck Surg* 2016;24:500-4.
- Verhaegen VJ, Feuth T, van den Hoogen FJ, Marres HA, Takes RP. Endoscopic carbon dioxide laser diverticulostomy versus endoscopic staple-assisted diverticulostomy to treat Zenker's diverticulum. *Head Neck* 2011;33:154-9.
- Payne WS, King RM. Pharyngoesophageal (Zenker's) diverticulum. *Surg Clin North Am* 1983;63:815-24.
- Baron SH. Zenker's diverticulum as a cause for loss of drug availability: a "new" complication. *Am J Gastroenterol* 1982;77:152-3.
- Cope R, Spargo P. Anesthesia for Zenker's diverticulum. *Anesth Analg* 1990;71:312.
- Ovassapian A, Salem MR. Sellick's maneuver: to do or not do. *Anesth Analg* 2009;109:1360-2.
- El-Orbany M, Connolly LA. Rapid sequence induction and intubation: current controversy. *Anesth Analg* 2010;110:1318-25.
- Banoub M, Kraenzler E. Anesthesia for pulmonary and mediastinal surgery. In: Estafanous F, Barash P, Reves J, eds. *Cardiac anesthesia: principles and practice*. 2nd ed. Philadelphia, PA: Lippincott Williams and Wilkins, 2001:703-67.
- Naja ZM, Al-Tannir MA, Zeidan A, Oweidar M, El-Rajab M, Ziade FM, et al. Bilateral guided cervical block for Zenker diverticulum excision in a patient with ankylosing spondylitis. *J Anesth* 2009;23: 143-6.
- Adams CF. Regional anesthesia for repair of Zenker's diverticulum. *Anesth Analg* 1990;70:676.