JOURNAL of ANESTHESIA and PERIOPERATIVE MEDICINE

Original Article

Intra-Aortic Balloon Occlusion for Pelvic and Sacrum Tumors: A Case Series

Kai Sun[1], Yang-Fan Huo[2], Yong Xu[1], Feng-Jiang Zhang[1], Shui Yu[1], Zhen-Feng Zhou[1], Li-Na Yu[1], and Min Yan[1]

ABSTRACT

Background: The purpose of this study is to investigate feasibilities of intra-aortic balloon occlusion (IABO) for pelvic and sacrum tumors, focusing on the advantages and precautions of the technique.

Methods: From January 2010 to December 2013, among all patients with sacrum or pelvic tumor, 46 underwent surgery adjuvant with IABO. We retrospectively reviewed the medical records of these patients, including characteristics, intraoperative hemorrhage, transfusion, serum potassium, arterial lactic acid, postoperative complication, tumor recurrence or metastasis at a follow-up of 28.2 months.

Results: Balloons for 46 patients were successfully placed, and the average intraoperative hemorrhage was 1.8 (1.2-3.0) l. Intraoperatively, arterial lactic acid increased from baseline (1.69±0.68) mmol/l to (2.11±0.82) mmol/l (P=0.17) during occlusion and (3.50±2.70) mmol/l (P=0.02) after deflation. While serum potassium concentration showed a trend of increase, but the change was not significant. Application of the technique helped create a bloodless surgical field and shorten the operative time. 9 patients regained normal defecation, while 2 patients with preoperative numbness of perineum developed new onset urinary and fecal incontinence after surgery. Postoperatively, 5 patients developed wound infection, 1 patient developed lower limb weakness, and 1 patient developed cerebrospinal leak. During 28.2 months' follow-up, 5 recurrences and 2 metastases occurred.

Conclusions: IABO might be a choice to reduce intraoperative bleeding, create a clear view of the anatomical structures, shorten the operative time and limit postoperative complication in resection of pelvic and sacrum tumor. Nevertheless, anesthesiologists and surgeons should be sensitive to hemodynamic parameters, electrolyte balance as well as acid-base balance during the procedure, especially after deflation of the balloon. (Funded by the Department of Anesthesiology, The Second Affiliated Hospital, Zhejiang University School of Medicine, China.)

From [1]Department of Anesthesiology, The Second Affiliated Hospital, Zhejiang University School of Medicine, Hangzhou, China; [2]Weifang Medical University, Weifang, China.

Correspondence to Dr. Min Yan at zryanmin@zju.edu.cn.

Citation: **Kai Sun, Yang-Fan Huo, Yong Xu, Feng-Jiang Zhang, Shui Yu, Zhen-Feng Zhou, et al. Intra-Aortic balloon occlusion for pelvic and sacrum tumors: a case series. *J Anesth Perioper Med* 2018; 5: 17-22.**

doi: **10.24015/JAPM.2017.0029**

Surgical resection of large pelvic and sacrum tumors is complex and challenging for both surgeons and anesthesiologists, based on the proximity of blood vessels and nerves. Blood loss is typically massive for these patients and sometimes, it could be life-threatening. Up to now, several methods have been developed to control intraoperative hemorrhage, including controlled hypotensive anesthesia, unilateral or bilateral internal iliac artery ligation before tumor excision, preoperative selective arterial embolization (1), and most importantly, intra-aortic balloon occlusion (IABO).

IABO has been described for successful temporary hemostasis for severe active bleeding, such as ruptured abdominal aortic aneurysm (2, 3), abdominal trauma (4), gastrointestinal bleeding (5), postpartum hemorrhage (6) and pelvic fractures (7). In 2005, Mi C et al. (8) applied the technique in upper sacral tumors, and gained satisfying effectiveness. Subsequent case reports supported the result (9-16), but the sample size is still limited.

During recent 4 years, our medical center has performed 46 cases of IABO for pelvic and sacrum tumor excision. We reviewed all of these patients to share our experience of application of the technique, especially advantages and precautions of the technique from an anesthetist's aspect.

METHODS

Patients

From January 2010 to December 2013, 46 patients were diagnosed as sacrum or pelvic tumor and benefitted from IABO during orthopedics surgery in the Second Affiliated Hospital of Zhejiang University. All of these patients were reviewed and analyzed in this study. There were 23 men and 23 women with an average age of 42 years (range 16-68 years). The follow-up ranged from 2 to 53 months with an average time of 28.2 months. The chief complaint of the subjects included hip or leg pain, abnormal defecation, numbness, limitation of motion, lower limb swelling and distension. The lesion located in sacrum or pelvis with mean tumor size estimated by the maximum tumor diameter in each case was 15.1 cm (range 6-30 cm). The demographic and clinical characteristics of these patients are summarized in Table 1.

Abdominal Aorta Occluding Technique

The IABO application was approved by the hospital Research and Ethics Committee, and written informed consent was obtained from all patients. If a large amount of blood loss was expected, such as the tumor involving lumbar vertebrae, or the tumor being suspected or confirmed as giant cell tumor preoperatively, or marginal resection being planned, then controlled hypotensive anesthesia and IABO were required. A sophisticated anesthetist was responsible for evaluating patient's basic condition, and whether there were contraindications for IABO or not, which mainly included local infection around optional puncture point, invasion of feasible artery for puncturing and presence of abdominal aortic plaque/calcification or vascular malformation. X-ray and ultrasonic examination of abdominal aorta, external iliac artery and femoral artery were routinely processed for these patients.

The procedure was performed by two sophisticated anesthetists and an experienced interventional radiologist. Anesthesia was induced with etomidate 0.1-0.4 mg/kg and sufentanil 0.5-1.0 μg/kg, and then rocuronium 0.6 mg/kg was administered to provide neuromuscular blockade for tracheal intubation. Anesthesia was maintained with adjusted propofol and remifentanil infusion to maintain the bispectral index (BIS) 40-50. After anesthesia induction, the groin region was sterilized with iodine solution. Then the integrity of the balloon was checked (Figure 1) and all the canals were heparinized. A 10-Fr sheath was inserted into lesion-contralateral femoral artery and the air-free double-lumen sizing balloon catheter (Cordias, Johnson & Johnson, USA) was inserted through the sheath to reach the abdominal aorta. The balloon was located between the renal artery branch and the abdominal aortic bifurcation. Approximate depth was the distance between the access point and the umbilicus, while the position was accurately confirmed by a mobile X-ray apparatus (Figure 2). The balloon was gradually filled with 6-12 ml of heparin solution until oxygen saturation of bilateral toes disappeared. Before emptying the bal-

loon, ultrasonography was used to detect bilateral renal artery flow to ensure abundant perfusion of kidneys. Then the catheter was fixed and the balloon was deflated. Afterwards, a bolus of heparin was administered to achieve the activated clotting time of 200-250 seconds and the patient was prepared for surgery. During the surgery, heparin was continuously infused until evacuation, to prevent thrombosis. When the tumor was exploded, the balloon was gradually filled with heparin solution. If the resection process was longer than 60 minutes, then a 10 minutes' deflation was required. After complete resection of the tumor, the balloon was gradually deflated to prevent fluctuation of hemodynamics.

During the occlusion, the blood pressure might increase and antihypertensive drugs were needed to avoid unexpected complications while after deflation, hypotension was the main concern. All through the operation, vasoconstrictor/vasodilator was administered if necessary according to the attending anesthesiologist. Intraoperatively and postoperatively, urine volume and perfusion of the lower limbs were closely monitored. The patient was transported to intensive care unit (ICU) if necessary.

Data Collection and Statistical Analysis

Perioperative data were retrospectively reviewed, including operative duration, anesthesia duration, occlusion duration, intraoperative hemorrhage, intraoperative transfusion, in-hospital fee, length of hospital days, postoperative complication and tumor recurrence/metastasis at 28.2 months' follow-up. Also, serum potassium and arterial lactic acid was continuously recorded before occlusion, during occlusion and immediately after deflation. Serum creatinine was continuously monitored before occlusion and daily during the first 2 days postoperatively. Post-occlusion acute kidney injury was defined by the AKIN criteria (a percentage increase in creatinine by ⩾1.5-fold from preoperative level or an absolute increase creatinine Cr ⩾0.3 mg/dl within 48 hours) (17). Continuous data are presented as mean±standard deviation or median (interquartile range) according to their distribution and categorical data are presented as numbers. Indicators changing over time were assessed using repeated measures analysis of variance. The statistical analysis was performed using SPSS software (version 11.0; SPSS, Chicago, IL, USA). The level of significance was a probability value of <0.05.

Table 1. Preoperative Patient Characteristics (n=46).

Age (yr)	42±16
Gender (Male/Female)	23/23
Weight (kg)	60±14
Body mass index (kg/m^2)	22.0±4.1
Lesion location (sacrum/pelvis)	22/24
ASA (1/2/3)	2/41/3
Secondary surgery (Yes/No)	5/41
Preoperative hemoglobin (mg/dl)	14.7±1.0
Preoperative chief complaint	
Pain	30
Abnormal defecation	10
Numbness	6
Akinesia	4
Swelling	3

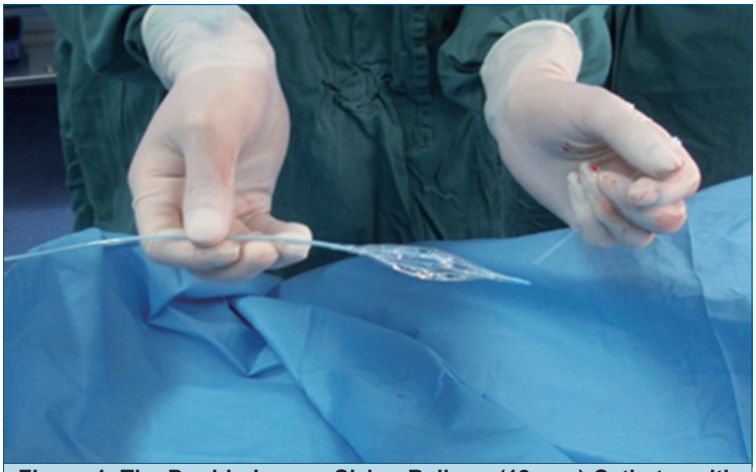

Figure 1. The Double-Lumen Sizing Balloon (18 mm) Catheter with an Intra-Aortic Occlusion Balloon.

RESULTS

The IABO was satisfying and surgery was successful in all patients. With the technique, less intraoperative hemorrhage was found and a bloodless surgical field was created. Characteristics of the 46 patients are summarized in Table 2. The final diagnosis was confirmed by postoperative pathological diagnosis, including 13 osteosarcomas, 12 chondrosarcomas, 9 chordomas, 4 giant cell tumors, 3 metastasis tumors from thyroid gland, 1 aneurysmal bone cyst, 1 myeloma, 1

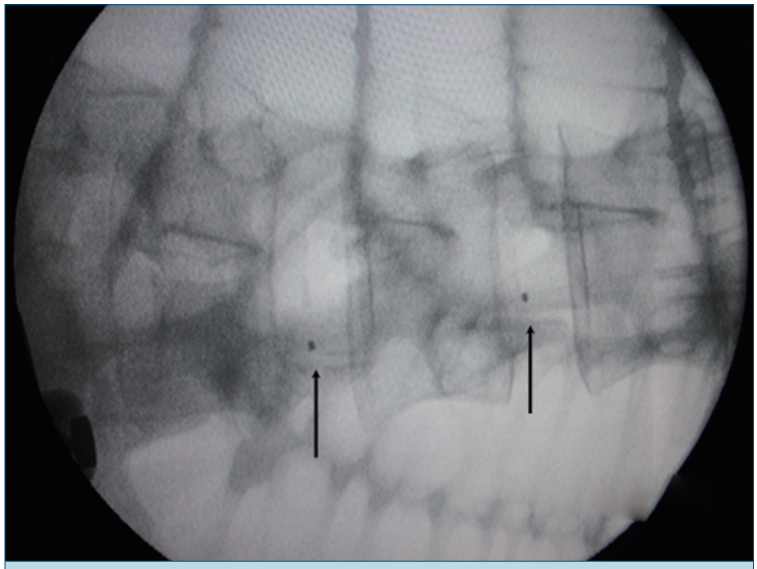

Figure 2. Two Markers (Black Arrows in the Figure) in the Two Ends of the Balloon which were Detected by the Bone X-ray to Verify Location of Balloon.

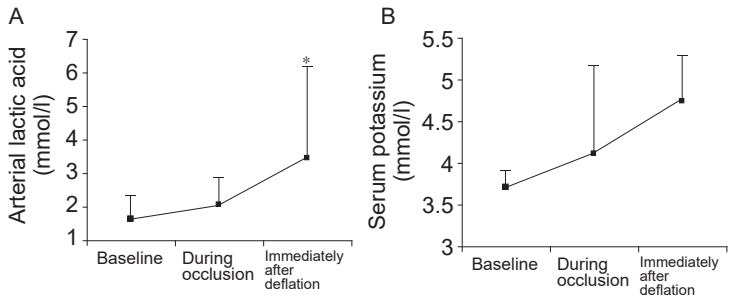

Figure 3. Arterial Lactic Acid and Serum Potassium Concentration at Different Time Point.
A. Arterial lactic acid at different time point; B. Serum potassium concentration at different time point. *P<0.05 compared with baseline value.

Table 2. Characteristics of the Patients Treated by IABO (n=46).

Occlusion duration (min)	51.5±26.0
Operative duration (min)	267.7±100.1
Anesthetic duration (min)	381.4±107.7
Isovolemic hemodilution (Yes/No)	5/41
Intraoperative vasoconstrictor (Yes/No)	19/27
Intraoperative vasodilator (Yes/No)	15/31
Blood loss (l)	1.8 (1.2-3.0)
Intraoperative urine output (ml/h)	159 (116-312)
Intraoperative resuscitation fluids (l)	4.5 (3.4-6.0)
Intraoperative red blood cell transfusion (l)	1.2 (0.8-2.4)
Intraoperative plasma transfusion (l)	0.8 (0.4-1.0)
Postoperative ICU stay (Yes/No)	22/24
Length of hospital days (d)	37.2±13.0
Length of postoperative hospital days (d)	21.7±10.9
Total cost (￥)	58680.3±38529.8

neurilemmoma, 1 fibrosarcoma and 1 fibromyxoidsarcoma.

Arterial lactic acid and serum potassium were consecutively monitored during and after the occlusion at different point (Figure 3). Repeated measures analysis of variance indicated significant difference of lactate concentration (P=0.03), but not potassium (P=0.34). During and after occlusion, arterial lactic acid increased from baseline (1.69 ± 0.68) mmol/l to (2.11 ± 0.82) mmol/l (P=0.17) and (3.50 ± 2.70) mmol/l (P=0.02), respectively. While serum potassium concentration increased from baseline (3.70 ± 0.22) mmol/l to (4.11 ± 1.06) mmol/l (P=0.19) and (4.75 ± 0.55) mmol/l (P=0.34), respectively.

Of all the patients, pain, numbness, swelling and distension were relieved by the surgery. 9 of 10 (90.0%) patients who suffered from abnormal defecation regained normal function postoperatively, but 2 (4.3%) patients with preoperative numbness of perineum developed new-onset urinary and fecal incontinence after surgery. 5 (10.9%) patients had wound infection ranging from minor dehiscence that did not require operative intervention (3/5) to major wound dehiscence that required additional procedure (2/5). 2 (4.3%) patients developed acute kidney injury postoperatively, but none required renal replacement therapy. 1 (2.2%) patient developed unilateral lower limb weakness, and 1 (2.2%) patient developed cerebrospinal leak after surgery. All the complications were treated conventionally and all the patients discharged satisfactorily. No symptomatic thrombotic or ischemic complication of the lower extremities happened. During 28.2 months' follow-up, 5 (10.9%) patients developed radiologically detectable recurrence and 2 (4.3%) metastases were found.

DISCUSSION

For pelvic and sacrum tumor, the main treatment strategy is surgery adjuvant with perioperative radiotherapy or chemotherapy. But extensive bleeding is always encountered due to abundant blood supply of the tumor from branches of the internal, external and common iliac vessels, and sometimes even from the abdominal aorta. It is reported the median blood loss of 29 patients who underwent sacrectomy was 3.9 l

(18). In our cases who underwent IABO, the mean total blood loss volume was 1.8 (1.2-3.0) l, indicating that application of IABO might be associated with less intraoperative blood loss, a clearer view of the anatomical structures, shortened operative time and to some extent, even reduced incidence of tumor recurrence and metastasis in resection of pelvic and sacrum tumor.

Up to now, there are 9 articles discussing the application of IABO on pelvic and/or sacrum tumors (8-16). 7 articles are case series or single-arm retrospective analysis with 30 cases or less (8-10, 12, 14-16), and 2 articles are retrospective studies with IABO group and non- IABO group (11- 13). All of these authors believed IABO was associated with less intraoperative blood loss and different authors focused on different aspects, such as hemodynamic changes, postoperative complications or the prognosis of the tumor. But to our knowledge, few of them focused on the homeostasis from an anesthetist's aspect because generally speaking, the balloon is placed and managed by radiologists, whose focus are different. We are the first to discuss the advantages and precautions, especially homeostasis which is critical to patients' outcome as demonstrated as following, from an anesthetist's aspect.

During and after reperfusion of lower limbs, an increase in lactate concentration and potassium appeared, as a result of extracellular potassium and lactic acid accumulated by ischemia flying into systemic circulation. The same phenomenon was observed in animals and humans during cross clamping of the aorta (19). Lactic acid was demonstrated to be associated with increased mortality and morbidity in different clinical models (20, 21). And hyperkalemia is well known as a common cause of arrhythmia and even asystole. In this respect, anesthesiologists and surgeons should pay attention to hemodynamic parameters, serum potassium and acid-base balance during occlusion and after deflation of the balloon. Gradual deflation shortened occlusion time might be helpful to prevent severe consequences. Antihypertensive drugs or vasoconstrictors should be considered if necessary.

Common complication of IABO includes femoral artery/aortic thrombosis (22), local hematoma, infection, sexual dysfunction, urinary and fecal incontinence, bowel dysfunction and lower extremity impairment. It is reported that in the majority of patients, unilateral resection of sacral roots or preservation of at least one S3 root in bilateral resection could preserve bowel and bladder function (23). In our case series, 90.0% of patients regained normal bladder function while 4.3% of patients developed new onset urinary and fecal incontinence. Considering the fact that preoperative numbness of perineum exists, the lesion itself and surgical resection extent should be the main influencing factor. The prevalence of cerebrospinal fluid leakage was 4.5% as reported (18). In our case series, 1 (2.2%) cerebrospinal fluid leakage was found, which was attributed to injury to the dura and cauda. Compared to previous wound- healing disturbances rate (29.2%) (12), 10.9% of patients in our study developed wound infection. Although the balloon was placed in the abdominal aorta bellow the renal artery, 4.3% patients got acute kidney injury postoperatively, which might be caused by decreased renal perfusion resulting from hypotension after deflation. No femoral artery/aortic thrombosis was detected, partly because intraoperative heparinization and the balloon was inflated with air-free heparin solution instead of air. No local hematoma happened as a result of 30 minutes' compression and 24 hours' pressure dressing. It's different to compare the recurrence and metastases with literatures, because the group is made up of different pathological diagnosis.

Our study has some limitations. First is the retrospective nature of this study. Because the surgery was operated by different anesthetists and different surgeons, they had different standards for vasoactive agents and had their own subjective evaluation of blood loss, instead of exact measurement. Second, based on the fact that the location and size of the lesion greatly influenced the hemorrhage, the indication for IABO was not that solid individually.

CONCLUSION

In conclusion, IABO might be a choice to reduce intraoperative bleeding, to create a clear view of the anatomical structures, to shorten the operative time and to limit postoperative compli-

cation in resection of pelvic and sacrum tumor. Nevertheless, anesthesiologists and surgeons should be sensitive to hemodynamic parameters, electrolyte balance as well as acid-base balance during the procedure, especially after deflation of the balloon.

This study was funded by the Department of Anesthesiology, The Second Affiliated Hospital, Zhejiang University School of Medicine, Hangzhou, China.

The authors declare no other conflicts of competing interest for this work.

References

1. Broaddus WC, Grady MS, Delashaw JB Jr, Ferguson RD, Jane JA. Preoperative superselective arteriolar embolization: a new approach to enhance resectability of spinal tumors. *Neurosurgery* 1990;27:755-9.
2. Tsilimparis N, Saleptsis V, Rohlffs F, Wipper S, Debus ES, Kölbel T. New developments in the treatment of ruptured AAA. *J Cardiovasc Surg (Torino)* 2016;57:233-41.
3. Malina M, Holst J. Balloon control for ruptured AAAs: when and when not to use? *J Cardiovasc Surg (Torino)* 2014;55:161-7.
4. Ogura T, Lefor AT, Nakano M, Izawa Y, Morita H. Nonoperative management of hemodynamically unstable abdominal trauma patients with angioembolization and resuscitative endovascular balloon occlusion of the aorta. *J Trauma Acute Care Surg* 2015;78:132-5.
5. Sano H, Tsurukiri J, Hoshiai A, Oomura T, Tanaka Y, Ohta S. Resuscitative endovascular balloon occlusion of the aorta for uncontrollable nonvariceal upper gastrointestinal bleeding. *World J Emerg Surg* 2016;11:20.
6. Chen M, Xie L. Clinical evaluation of balloon occlusion of the lower abdominal aorta in patients with placenta previa and previous cesarean section: A retrospective study on 43 cases. *Int J Surg* 2016;34:6-9.
7. Costantini TW, Coimbra R, Holcomb JB, Podbielski JM, Catalano R, Blackburn A, et al. Current management of hemorrhage from severe pelvic fractures: Results of an American Association for the Surgery of Trauma multi-institutional trial. *J Trauma Acute Care Surg* 2016;80:717-23;discussion 723-5.
8. Mi C, Lu H, Liu H. Surgical excision of sacral tumors assisted by occluding the abdominal aorta with a balloon dilation catheter: a report of 3 cases. *Spine (Phila Pa 1976)* 2005;30:E614-6.
9. Yang L, Chong-Qi T, Hai-Bo S, Lan Z, Tian-Fu Y, Hong D, et al. Appling the abdominal aortic-balloon occluding combine with blood pressure sensor of dorsal artery of foot to control bleeding during the pelvic and sacrum tumors surgery. *J Surg Oncol* 2008;97:626-8.
10. Xue-Song L, Chao Y, Kai-Yong Y, Si-Qing H, Heng Z. Surgical excision of extensive sacrococcygeal chordomas assisted by occlusion of the abdominal aorta. *J Neurosurg Spine* 2010;12:490-6.
11. Luo Y, Duan H, Liu W, Min L, Shi R, Zhang W, et al. Clinical evaluation for lower abdominal aorta balloon occluding in the pelvic and sacral tumor resection. *J Surg Oncol* 2013;108:148-51.
12. Zhang L, Gong Q, Xiao H, Tu C, Liu J. Control of blood loss during sacral surgery by aortic balloon occlusion. *Anesth Analg* 2007;105:700-3.
13. Tang X, Guo W, Yang R, Tang S, Dong S. Use of aortic balloon occlusion to decrease blood loss during sacral tumor resection. *J Bone Joint Surg Am* 2010;92:1747-53.
14. Guo W, Ji T, Tang X, Yang Y. Outcome of conservative surgery for giant cell tumor of the sacrum. *Spine (Phila Pa 1976)* 2009;34:1025-31.
15. Honda H, Yoshida T, Shibue C, Baba H. Use of aortic occlusion balloon catheter for sacral giant cell tumor resection. *Masui* 2012;61:610-3.
16. Gong HS, Liu GJ, Huang QS, Chen FH, Zhao HB. Surgical Management of Sacrococcygeal Region Giant Tumors by Use of Balloon Occlusion Abdominal Aorta. *Turk Neurosurg* 2016;26:904-11.
17. Mehta RL, Kellum JA, Shah SV, Molitoris BA, Ronco C, Warnock DG, et al. Acute Kidney Injury Network: report of an initiative to improve outcomes in acute kidney injury. *Crit Care* 2007;11:R31.
18. Fourney DR, Rhines LD, Hentschel SJ, Skibber JM, Wolinsky JP, Weber KL, et al. En bloc resection of primary sacral tumors: classification of surgical approaches and outcome. *J Neurosurg Spine* 2005;3:111-22.
19. Gelman S. The pathophysiology of aortic cross-clamping and unclamping. *Anesthesiology* 1995;82:1026-60.
20. Lopez-Delgado JC, Esteve F, Javierre C, Torrado H, Rodriguez-Castro D, Carrio ML, et al. Evaluation of Serial Arterial Lactate Levels as a Predictor of Hospital and Long-Term Mortality in Patients After Cardiac Surgery. *J Cardiothorac Vasc Anesth* 2015;29:1441-53.
21. Vibert E, Boleslawski E, Cosse C, Adam R, Castaing D, Cherqui D, et al. Arterial Lactate Concentration at the End of an Elective Hepatectomy Is an Early Predictor of the Postoperative Course and a Potential Surrogate of Intraoperative Events. *Ann Surg* 2015; 262:787-92;discussion 792-3.
22. Sakakibara Y, Sasaki A, Nakata H, Osaka M, Hiramatsu Y, Mitsui T. Acute aortic thrombosis after intra-aortic balloon pumping. *Jpn J Thorac Cardiovasc Surg* 2000;48:123-5.
23. Todd LT Jr, Yaszemski MJ, Currier BL, Fuchs B, Kim CW, Sim FH. Bowel and bladder function after major sacral resection. *Clin Orthop Relat Res* 2002:36-9.