

## Case Report

# Lidocaine Infusion Treatment for Trigeminal Neuralgia Due to Vertebrobasilar Dolichoectasia in a Patient after Right Thyroidectomy

Tuan T. Tran, Daryl I. Smith, and Nobuyuki-Hai T. Tran

## ABSTRACT

The treatment of neuropathic pain of all sources can be particularly daunting. This is especially true when this type of pain arises unpredictably in an otherwise “routine” setting. In this work, we discuss a case in which a 72-year-old man with multiple medical problems (among them are coronary artery disease, hypertension, a basilar artery cerebral aneurysm, and multiple cancerous thyroid nodules) who underwent an otherwise uneventful right thyroidectomy. Following this procedure, he developed intractable trigeminal neuralgia believed to be the result of vertebrobasilar dolichoectasia. The neuralgia proved to be refractory to the standard pharmacologic treatments which included carbamazepine, opiates, and gabapentoids. With both the explicit written and verbal consent of this patient, we discuss his case as well as possible pathogenic mechanisms that may have come into play with special attention to post-operative vascular changes. In addition, the use of lidocaine and one of its less well known neuropharmacological mechanisms of action is examined as one explanation of its effectiveness in this setting.

From the Department of Anesthesiology and Pain Management, University of Rochester, Rochester, NY, USA.

**Correspondence** to Dr. Nobuyuki-Hai T. Tran at [nobuyukihai\\_tran@urmc.rochester.edu](mailto:nobuyukihai_tran@urmc.rochester.edu).

**Citation:** Tuan T. Tran, Daryl I. Smith, Nobuyuki-Hai T. Tran. Lidocaine Infusion Treatment for Trigeminal Neuralgia Due to Vertebrobasilar Dolichoectasia in a Patient after Right Thyroidectomy. *J Anesth Perioper Med* 2018; 5:355-358.

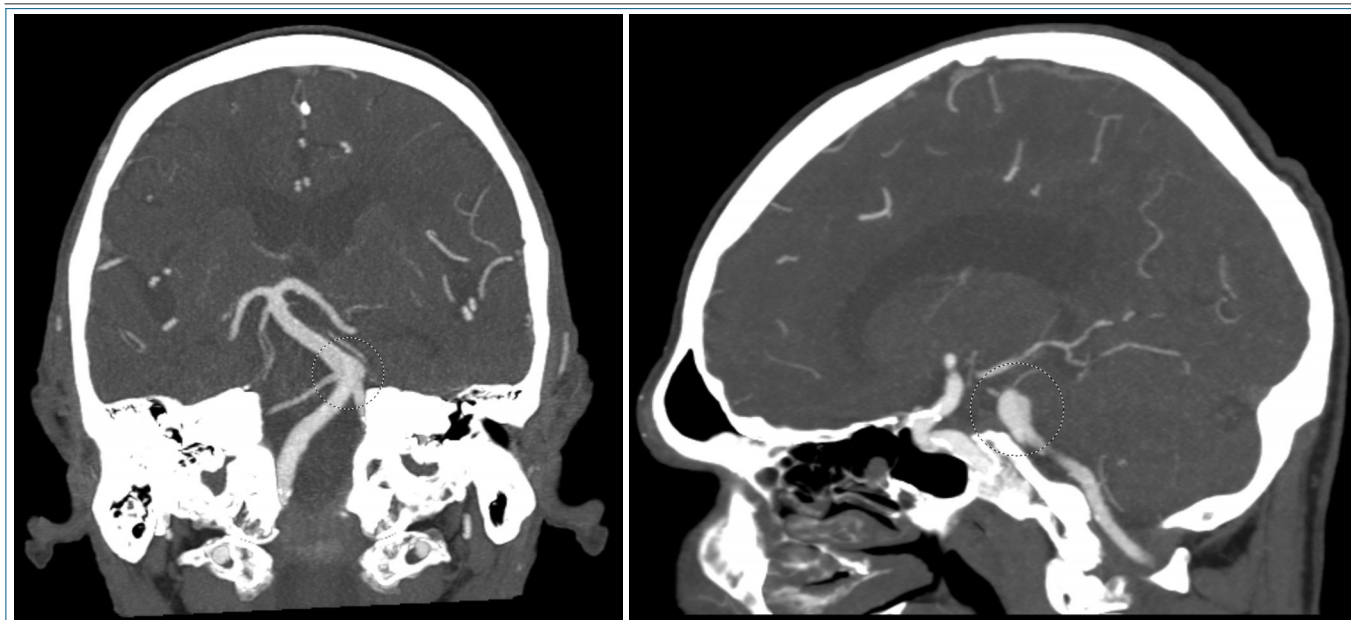
doi: 10.24015/JAPM.2018.0053

Intravenous infusion of lidocaine for pain control has been described in the literature but remains infrequently used in the treatment of certain pain syndromes. The mechanism of action of lidocaine, blockade of voltage-dependent sodium channels is similar to that of carbamazepine (1), the mainstay of treatment for trigeminal neuralgia. Lidocaine may also provide prolonged analgesia through the action of a metabolite, monoethyl glycine xylidide (MEGX), which inhibits the astrocytic glycine transporter (Gly T-1) and increases synaptic concentrations of glycine (2). Glycine may then act to inhibit the release of glutamate, an important CNS excitatory peptide (3, 4). Carbamazepine has also been demonstrated to inhibit excitatory glutamatergic transmission. After obtaining written and verbal consent

from this patient we describe the successful management of refractory trigeminal neuralgia which occurred following right thyroidectomy using an intravenous lidocaine infusion (5-7).

## Case Presentation

The patient is a seventy-two years old male with multiple medical problems which include coronary artery disease, chronic obstructive pulmonary disease, hypertension, Alzheimer's disease, a basilar artery cerebral aneurysm, right subcortical lacunar infarcts and cancerous thyroid nodules. The patient subsequently underwent a right thyroidectomy. Less than six months following the procedure he began experiencing left sided



**Figure. CT Scan Showing Coronal (left) and Sagittal (right) Views with Labeled Segments of the Dolichoectatic Vertebrobasilar System.**

lower gum line pain which was intermittent and severe. He characterized the pain as stabbing in nature and stated that it typically lasted for approximately 10 to 30 seconds at a time. He reported that over time the pain became more frequent and was affecting his eating and drinking to the point where he no longer attempted those essential activities. Physical examination revealed that the pain and tenderness existed in the distribution of the left inferior alveolar nerve, a branch of the V3 component of the trigeminal nerve.

A mandibular CT scan was obtained to rule out an osseous lesion; and a CT angiogram was obtained which revealed diffuse vertebrobasilar dolichoectasia with aneurysmal distension of 8.6–9.5 mm (Figure).

This was unchanged from a prior CT angiogram performed before the right thyroidectomy. It is important to note that both CT angiograms revealed particular involvement at the pre-pontine cistern at the level of the left trigeminal exit. The patient was diagnosed with trigeminal neuralgia secondary to left vertebrobasilar dolichoectasia (VBD). Initial management included titrating dosages of carbamazepine and opioids with-

out significant improvement. Pregabalin was added to the treatment course without significant improvement. The Acute Pain Service was consulted for evaluation of treatment options for refractory trigeminal neuralgia. The patient agreed to and was consented for an intravenous lidocaine infusion.

The patient was given 50-milligram doses of intravenous lidocaine at 5-minute intervals with a target of a clinical response or a maximal dose of 5 mg/kg. At the 2.45 mg/kg dose mark the patient reported that his pain had decreased to 0/10 on the visual analog scale (VAS). He tolerated the procedure well with no chest pain, shortness of breath or palpitations; and his vital signs remained stable and acceptable.

### Discussion

We entertain at least two potential causatives or contributing factors in this case: a vascular factor and a neuronal factor. These may have acted alone or together to initiate the observed pain syndrome. Under normal circumstances, the relationship between thyroid and carotid artery blood flow while interrelated is not a cause of oro-facial

pain or headache. However, Linskey et al. in a 1994 study reported that 2% of 1404 consecutive patients with typical trigeminal neuralgia who underwent microvascular decompression were found to have vascular compression by the vertebral or the basilar artery an anatomical condition that was similar to that of our patient. This subgroup was older and predominantly male when compared to the remainder of those studied (8). The work serves to help delineate the role the vertebral and basilar arteries may play in this syndrome. In another work, Macchi et al. described the perfusion of an internal and external carotid artery system via anastomotic connections from the contralateral superior thyroid artery to the ipsilateral superior thyroid artery (9). In our patient, the relationship of arterial perfusion in the cervical region may have created an environment in which post-surgical alterations in blood flow following ligation of the thyroid arteries impacted the compressive nature of the dolichoectatic segment of the vertebrobasilar system at the left trigeminal exit. A second cause of the onset of symptoms may lie in the injury to the nerve supply of the thyroid gland. The innervation of the thyroid gland is via the superior, middle and inferior sympathetic ganglia (stellate ganglion). Sectioning of these nerves during thyroidectomy may have caused the development of a sympathetically mediated neuropathic process akin to a second crush injury pattern with remote site involvement (10) or, more likely, a variant of a spreading complex regional pain syndrome phenomenon in which at risk trigeminal fibers were activated despite their remote anatomical location (11-13). The neuronal sectioning argument for the development of this patient's pain is most consistent with the time course of the development of this patient's symptoms. Finally, headache and posterior neck pain have been previously described following thyroidectomy. The proposed mechanism of postoperative headache and posterior neck pain implicates the vulnerability of the greater occipital nerve during hyperextension of the neck. In this position it is theorized that the nerve is subject to entrapment at two points: the arch of C1 and the lamina of C2; and the point at which it passes through the aponeurotic attachment of the trapezius and the sternocleidomastoid muscle (14). While our patient voiced no complaint of a severe headache

or cervicgia, it is possible that primary pain generators in these locations could have resulted in orally referred pain patterns (15, 16).

It should be noted that one study has suggested that local anesthetic infiltration may reduce post thyroidectomy pain at the surgical site but this does not describe trigeminal neuralgia (17). A recent systematic review of the literature by Xu, et al. found no randomized, controlled trials that examined intravenous lidocaine infusion as a treatment for neuropathic pain. The review did emphasize the value of intravenous regional blockade as a treatment for the complex regional pain syndrome (CRPS) variant of neuropathic pain in the extremities (18), and concluded, based upon a paper previously cited in this case report (Tremont-Lukats, 2006) that intravenous lidocaine 5 mg/kg/h was more effective than saline placebo in relieving spontaneous CRPS extremity pain, but that lower doses of lidocaine (1 or 3 mg/kg/h) were no better than placebo in relieving this pain (6). The limitations of lidocaine infusion for neuropathic pain are its side effects and toxicity. Common side effects of lidocaine infusion are hypotension, hypertension, and headache. Serious and uncommon side effects include supraventricular tachycardia, and pulmonary edema (19).

Carbamazepine remains the first-line treatment for patients with trigeminal neuralgia. When Carbamazepine and oxcarbazepine cannot be used the alternative, evidenced-based treatments are lamotrigine and baclofen. Phenytoin, clonazepam, valproic acid, and gabapentin may also be tried, but it is important to note that they are not evidence-based treatments for trigeminal neuralgia. Sympathetic blockade of the stellate ganglion can be performed should the pain is resistant. For our patient, sympathetic blockade was not attempted due to his excellent response to intravenous lidocaine. When acute exacerbations of TN with frequent, easily triggered, high-intensity pain attacks occur, effective interventions are needed which will allow the patient to engage in essential activities of daily living. In such cases, intravenous lidocaine infusions specifically because of its less well-known glycinergic effect may be indicated.

The patient described in this report required no further intravenous infusion treatment and was discharged home with adequate analgesia. Unfor-

**Take home messages.**

- Lidocaine is an effective treatment of trigeminal neuralgia.
- Complex regional pain syndrome can develop distantly away from the original location of the injury.
- The significance of recognizing the specific pre-operative co-morbidities as contributing factors in the development of neuropathic pain syndromes in the peri-operative period.
- Implementing pre-operative therapies that prevent or reduce the likelihood of developing neuropathic pain syndromes.

Unfortunately, the duration of effective analgesia following the lidocaine treatment was not known due to loss of follow up. The results, in this case, are promising, and as indicated by the literature supporting these findings, continued research is needed to examine the efficacy of, and to clarify the specific indications for, intravenous lidocaine infusion treatment for refractory neuropathic pain syndromes. Of perhaps equal clinical significance is the need to examine pre-operative co-morbidities that could increase the likelihood of the development of neuropathic pain syndromes in the peri-operative period, especially in patients undergoing otherwise routine procedures. In this case, the circulatory relationship between the blood supply of the thyroid gland and the vertebrobasilar circulation in a patient with vascular disease may have created a unique setting which generated severe, refractory pain. The potential avoidance of this pain may have depended upon the ability to recog-

nize and intervene with therapies in the perioperative period. Clinical studies correlating specific co-morbidities processes with “routine” surgical procedures and the development of pain syndromes are needed to improve post-surgical outcomes.

**Conclusion**

Lidocaine is an effective treatment of trigeminal neuralgia. Complex regional pain syndrome can develop distantly away from the original location of the injury. The significance of recognizing the specific pre-operative co-morbidities as contributing factors in the development of neuropathic pain syndromes in the peri-operative period. Implementing pre-operative therapies that prevent or reduce the likelihood of developing neuropathic pain syndromes.

The authors declare no conflicts of interest.

**References**

1. Catterall WA. Molecular mechanisms of gating and drug block of sodium channels. *Novartis Found Symp* 2002;241:206-18.
2. Werdehausen R, Kremer D, Brandenburger T, Schlösser L, Jadasz J, Küry P, et al. Lidocaine metabolites inhibit glycine transporter 1: a novel mechanism for the analgesic action of systemic lidocaine? *Anesthesiology* 2012;116(1):147-58.
3. Attwell PJ, Singh Kent N, Jane DE, Croucher MJ, Bradford HF. Anticonvulsant and glutamate release-inhibiting properties of the highly potent metabotropic glutamate receptor agonist (2S,2'R, 3'R)-2-(2', 3'-dicarboxycyclopropyl)glycine (DCG-IV). *Brain Res* 1998;805(1-2):138-43.
4. Fei Z, Zhang X, Bai HM, Jiang XF, Wang XL. Metabotropic glutamate receptor antagonists and agonists: potential neuroprotectors in diffuse brain injury. *J Clin Neurosci* 2006;13(10):1023-7.
5. Gronseth G, Cruccu G, Alksne J, Argoff C, Brainin M, Burchiel K, et al. Practice parameter: the diagnostic evaluation and treatment of trigeminal neuralgia (an evidence-based review): report of the Quality Standards Subcommittee of the American Academy of Neurology and the European Federation of Neurological Societies. *Neurology* 2008; 71(15): 1183-90.
6. Tremont-Lukats IW, Hutson PR, Backonja MM. A randomized, double-masked, placebo-controlled pilot trial of extended IV lidocaine infusion for relief of ongoing neuropathic pain. *Clin J Pain* 2006; 22(3): 266-71.
7. Sindrup SH, Jensen TS. Pharmacotherapy of trigeminal neuralgia. *Clin J Pain* 2002;18(1):22-7.
8. Linskey ME, Jho HD, Jannetta PJ. Microvascular decompression for trigeminal neuralgia caused by vertebrobasilar compression. *J Neurosurg* 1994; 81(1): 1-9.
9. Macchi C, Catini C. The anatomy and clinical importance of the collateral circle between the external carotid arteries through an anastomosis between the superior thyroid arteries. *Ital J Anat Embryol* 1993; 98(3):197-205.
10. Russell BS. Carpal tunnel syndrome and the “double crush” hypothesis: a review and implications for chiropractic. *Chiropr Osteopat* 2008;16:2.
11. van Rijn MA, Marinus J, Putter H, Bosselaar SR, Moseley GL, van Hilten JJ. Spreading of complex regional pain syndrome: not a random process. *J Neural Transm (Vienna)* 2011;118(9):1301-9.
12. Maleki J, LeBel AA, Bennett GJ, Schwartzman RJ. Patterns of spread in complex regional pain syndrome, type I (reflex sympathetic dystrophy). *Pain* 2000;88(3):259-66.
13. Veldman PH, Goris RJ. Multiple reflex sympathetic dystrophy. Which patients are at risk for developing a recurrence of reflex sympathetic dystrophy in the same or another limb. *Pain* 1996;64(3): 463-6.
14. Barua SM, Mishra A, Kishore K, Mishra SK, Chand G, Agarwal G, et al. Effect of Preoperative Nerve Block on Postthyroidectomy Headache and Cervical Pain: A Randomized Prospective Study. *J Thyroid Res* 2016;2016:9785849.
15. Wong CS, Wong SH. A new look at trigger point injections. *Anesthesiol Res Pract* 2012;2012:492452.
16. Alvarez DJ, Rockwell PG. Trigger Points: Diagnosis and Management. *Am Fam Physician* 2002;65(4): 653-60.
17. Dieudonne N, Gomola A, Bonnichon B, Ozier YM. Prevention of postoperative pain after thyroid surgery: a double-blind randomized study of bilateral superficial cervical plexus blocks. *Anesth Analg* 2001; 92(6):1538-42.
18. Xu J, Yang J, Lin P, Rosenquist E, Cheng J. Intravenous Therapies for Complex Regional Pain Syndrome: A Systematic Review. *Anesth Analg* 2016;122 (3):843-56.
19. Raphael JH, Southall JL, Trehan GJ, Kitas GD. Efficacy and adverse effects of intravenous lignocaine therapy in fibromyalgia syndrome. *BMC Musculoskel-et Disord* 2002;3:21.