JOURNAL of ANESTHESIA and PERIOPERATIVE MEDICINE

Review Article

Transcatheter Aortic Valve Implantation: Complications and Anesthetic Management

Gang Zhang[1, 2]* , Jun Luo[1]*, Xiaoyan Huang[3]*, and Guo Chen[1]

ABSTRACT

Aim of review: This paper explains transcatheter aortic valve implantation's (TAVI) surgical complications, preventing strategies as well as its anesthetic management and choice.

Methods: By using the following keywords "complication", "transcatheter aortic valve implantation" and "anesthesia", literature for the past decades was searched and reviewed to identify articles on complications and anesthesia of TAVI.

Recent findings: TAVI is a new minimally invasive interventional surgery. Compared with the traditional surgery, TAVI doesn't need to be implemented with cardiopulmonary bypass (CPB). This operation is preferable to the patients with heart failure, advanced age and other high-risk factors. But there are still some corresponding complications after TAVI. Some severe complications such as stroke can seriously reduce the quality of patients' life, and the coronary occlusion can even directly led death of patients. We could also reduce the incidence of some complications by evaluating the patients' aortic root and choosing the proper valve.

Summary: This paper mainly reviews the latest research progress of several common or high-risk complications. For the patients' perioperative safety during TAVI, there are some specific preventions and treatments to reduce the incidence of the complications. Suitable anesthesia selection and management can also contribute to the low incidence of complications. (Funded by the Department of Anesthesiology, West China Hospital, Sichuan University.)

From the [1]Department of Anesthesiology, West China Hospital, Sichuan University; [2]Department of Anesthesiology, West China Second University Hospital, Sichuan University; Key Laboratory of Birth Defects and Related Diseases of Women and Children (Sichuan University), Ministry of Education; [3]the Operation Room of the Third People's Hospital of Chengdu; all in Chengdu, China.

*Contributed equally to this work.

Correspondence to Dr. Guo Chen at grace_chenguo@hotmail.com.

Citation: Gang Zhang, Jun Luo, Xiaoyan Huang, Guo Chen. Transcatheter Aortic Valve Implantation: Complications and Anesthetic Management. *J Anesth Perioper Med* 2018; 5: 215 - 220.

doi: 10.24015/JAPM.2018.0056

Aortic stenosis (AS) is one of the most common cardiac valvular diseases in adults (1). Calcific aortic stenosis is the main type in the older patients (2). Patients with calcific aortic stenosis can keep a long asymptomatic period, but once the clinical symptom appears, the prognosis is poor just through conservative internal treatment, and the mortality is higher than 50% in 2 years (3, 4). Surgical aortic valve replacement (SAVR) may also have a higher risk for these patients (5). Therefore, in order to reduce the risk of the operation and improve the patients' quality of life, TAVI comes into being. TAVI begins rather later in China, and its incidence of complications is still quite high. The complications can lead the extension of patients hospitalized dates and the growth of the expenses. Some severe complications such as stroke can seriously reduce the postoperative quality of patients' life, and the coronary occlusion can even directly led death of patients. For the particularity of TAVI, there is still no guidelines about anesthesia man-

agement and selection for this operation. This review mainly summarizes the complications and prevention of TAVI and introduces the management and selection of anesthesia.

Complications and Prevention

Peripheral Vascular Complications

The peripheral vascular complication is one of the common severe complications after TAVI, including vascular injury in puncture point and vascular path damage, and its incidence is related to the operator's experience, the degree of vascular calcification and the diameter ratio between sheath pipe and femoral artery (6). This complication can significantly increase mortality in patients, and it may lead pseudoaneurysm, arteriovenous fistula, retroperitoneal hemorrhage and iliac artery dissection (7). Kentaro observed 127 cases of femoral complications following TAVI, and the incidence is as high as 27% (8). Kahlert reported 101 TAVI patients (60 cases adopted through femoral artery), including 19 cases of puncture complications, 2 cases of retroperitoneal hematoma, 10 cases of iliac/femoral artery dissection, 3 cases of false aneurysm formation (9). Alsac reported 3 cases of blood vessel damage, including 2 cases of main artery dissection, 1 case of main artery rupture (leading the patient's death) (10). In order to reduce the incidence of peripheral vascular complications and choose an appropriate path, we can implement angiography to evaluate minimum inner diameter of the femoral artery and the extent of calcification and distortion before the operation.

Perivalvular Leakage and Valve Bracket Shifting

Perivalvular leakage is the main reason for the postoperative aortic regurgitation. This complication can be found in almost all the patients after TAVI. Most of the perivalvular leakages are mild without any Symptom, and with the extension of the postoperative time, it can be obviously improved. The incidence of moderate perivalvular leakage is about 20%, and which of severe perivalvular leakage is about 40%, reasoning out that the incidence of mild perivalvular leakage is about 40%. This complication can cause myocardial ischemia, ventricular dysfunction, heart failure and infective endocarditis. And significant stent shifting or valve tearing can cause severe hemodynamic disorder, which need the emergency treatment (11). Therefore, it is very important to choose the proper artificial valve and position accurately, which can be carried out by computed tomography (CT) or assessed by the transesophagus echocardiography (TEE). When the severe perivalvular leakage occured, the following ways can be taken to reduce valve regurgitation (11):

1. the expansion of artificial valve, which is obvious and is used commonly;
2. inserting a new bracket in the primary one, which is called “valve-in-valve”;
3. conservative treatments.

Conduction Block

The incidence of conduction block is very high after TAVI, which can achieve about 40%. Anatomical basis of this complication is that the atrioventricular node or His-bundle is adjacent to the aortic annulus (12). Masson, et al. reported, for the mechanical compression of artificial valve to the cardiac conduction system, the conduction block is more likely to occur, and the possibility of postoperative conduction block is related to the size of artificial valve and the oppressed time (13). The valve type is also related to the incidence of postoperative conduction block. Conduction system of CoreValve self-expanding valve (Figure 1) is more likely to be blocked than Edwards SAPIEN balloon expansion valve system (Figure 2). Because CoreValve self-expanding valve has a bigger volume, a deeper placement in left ventricular outflow and a bigger radial pressure to the cardiac conduction system. A large number of studies have also shown patients with CoreValve self-expanding valve were more easily to suffer the conduction block. By observing 53 cases of TAVI patients, Liang, et al. found CoreValve self-expanding valve was more likely to experience conduction block, the incidence was 42% and that of Edwards SAPIEN was just 8% (14). David reported permanent pacemaker implantation rate of CoreValve self-expanding valve was 35%, while that of Edwards SAPIEN was just 7%, which was significantly lower than the former (15). So for the patients with CoreValve , in order to ensure patients’ safety, it is necessary to implant

permanent pacemaker before operation if the patient complicated with right or left bundle branch block. For patients with no obvious abnormal electrocardiogram (ECG), intraoperative temporary pacemakers could be removed in 24 hours after the operation (16). For the patients with Edwards SAPIEN valve, temporary pacemaker can be removed after operation if the preoperative ECG is normal. For the patients, no matter what kind of artificial valve is implanted, conduction block can occur in any time, so all patients needs to be monitored for more than 3 days, especially the ECG (17).



Figure 1. Edwards SAPIEN Artificial Valve.

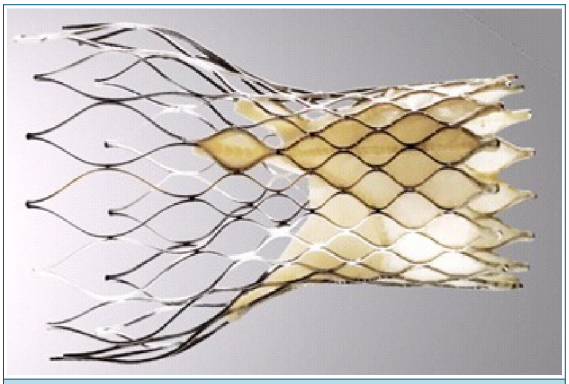

Figure 2. CoreValve Self-Expanding Valve.

Coronary Occlusion

This complication is rare and its incidence is about 0.6% - 7%. Once happens, it can lead acute heart failure, myocardial ischemia and shock, et al. (18). Coronary occlusion (Figure 3) is due to that the coronary ostium was obstructed by native calcified valves (Figure 4) or the apron like structure in prosthetic valve. According to a study in Canada, symptomatic coronary occlusion after transcatheter aortic valve placement is a rare but fatal complication. It is more easily occurs in women, and the left coronary artery is more likely to be obstructed (19). Patients with Edwards SAPIEN are more likely to experience this complication than CoreValve. It may be associated with two mechanisms: CoreValve self-expanding valve has a thinner structure, which can reduce the incidence of coronary artery occlusion (20); Edwards SAPIEN works by balloon dilation and the artificial valve has a higher position, which can shorten the distance from coronary ostium to aortic annulus (Figure 5) and lead the coronary occlusion easily.

Since this complication can cause serious consequence. TAVI should be implemented in the hybrid operating room. Once diagnosed, emergency measures must be taken, such as emergency percutaneous coronary intervention (PCI). Stabile reported 4 cases of left coronary obstruction, who were rescued by implemented emergency PCI (21). PCI is an effective and urgent measure to relieve coronary occlusion (Figure 6). If PCI can't be successful for patients, it is necessary to establish thoracotomy surgery under cardiopulmonary bypass.

Stroke

The incidence of stroke is 0%-10%, and the incidence of transient ischemic attack (TIA) is about 11% (10). For the friction between guidewire system and the vessel wall, it may lead the releasing of the embolus on the walls of vessels, including an atheromatous plaque. The high-risk factors of stroke include a long period of low blood pressure, air embolism, aortic valve embolus, aortic aneurysm and so on (22). The incidence of this complication through femoral artery is higher than that through the apex. Some literature reported the artificial conduction system can get maximum friction between the aortic arch and vessel wall, where lies the intracranial vascular branch. While the friction can significantly be re-

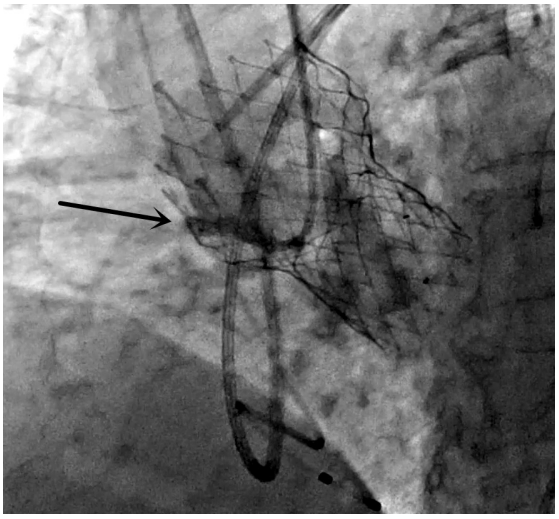

Figure 3. Angiography Showed the Right Coronary Obstruction (arrow).

Figure 4. CT Images Showed the Native Calcified Valves (arrow).

duced through apex, which can lower the probability of embolus releasing. So transapical approach can reduce the incidence of stroke after TAVI (23, 24). In order to prevent stroke, heparin should be used during TAVI, keeping the activated clotting time (ACT) 250-300 seconds. Aspirin and clopidogrel should also be used in 3-6 months after TAVI to prevent this complication (12).

Acute Kidney Injury (AKI)

AKI is a predictor of mortality after TAVI (25, 26), and it can not only increase the postoperative mortality, but increase the economic burden. Estimated glomerular filtration rate (eGFR), creatinine and blood urea nitrogen, can be used as the important indicators to evaluate the risk of AKI. Perioperative hemodynamic instability, inflammation and contrast can aggravate AKI as the patients' conditions are poor, complicated with severe aortic stenosis, heart failure and renal vascular sclerosis (27). History of myocardial infarction, chronic obstructive pulmonary disease (COPD), high logistic EuroSCORE, blood transfusion and hypertension are also the high-risk factors for AKI (21). So far, there is no specific treatment to reduce the incidence of AKI. However, stable hemodynamics, suitable amount of fluid therapy, renal perfusion, avoiding the renal toxic drugs can prevent AKI.

Valve Type Selection

In order to prevent the complications above, it is is very important to select the proper valve type. Preoperative evaluation of relevant computer tomography (CT) imaging or echocardiogram of aortic root can guide us to choose the right valve type. TAVI is still in its beginning stage in China, and we still lack the experience to choose the appropriate valve. Imaging evaluation methods including heart CT and echocardiography can provide us many important parameters about the aortic root such as a diameter of aortic annulus (28). CT imaging can help us evaluate the accurate distance from coronary ostium to the aortic annulus, but this way is restricted by contrast agent and the experience of the operator (29). For echocardiogram, some doctors reported: the TEE can not only rebuild the 3d structure of aortic annulus, but also display the distance from coronary ostium to the aortic annulus. Parameters provided by TEE would underestimate diameter of the aortic annulus, but the data has a strong consistency with that from CT, which can still be used as a good indicator to select artificial valve.

When choosing the proper type of valve, di-

ameter, perimeter and area of the aortic valve can be for our reference. When three indicators are consistent above, we can confirm the valve type. According to an expert consensus of TAVI from EAE/ASE in 2011 (30), the distance from coronary ostium to the aortic annulus can also be the reference for us to choose the type of valve. If the distance is 10-11 mm, it suggests choosing valve of type 23; if the distance is more than 11 mm, it suggests choosing valve of type 26; if the distance is less than 8 mm, even the minimum sizes of type can still lead the coronary occlusion.

Figure 5. The Distance from Coronary Ostium to Aortic Annulus (arrow).

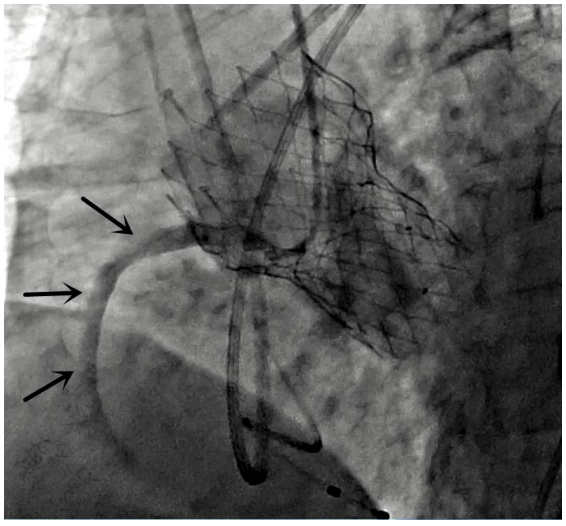

Figure 6. A right Coronary Occlusion Relieved after Emergency PCI (arrows).

Anesthetic Management

Before the operation, ECG, oxygen saturation, invasive arterial blood pressure and central venous pressure should be monitored. External defibrillation electrodes, vasoactive agents and so on should be prepared (31). TEE can help evaluate cardiac function, blood volume and state of artificial valves (32). The preoperative temporary pacemaker can not only provide rapid ventricular pacing(RVP), but timely treat atrioventricular block.

The primary goal of anesthetic management is to maintain stable hemodynamic state during TAVI. For the patients with enlarged left ventricle, we can maintain adequate preload by fluid therapy and lower the heart rate (50-70 times/min), extending the diastolic time, to increase coronary blood flow (33). Before the valve implantation, blood forward flow of aortic valve should be reduced to help the artificial valve position precisely. This can be achieved by RVP, which is the key step in TAVI. For RVP can increase the ventricular rate to about 180 times/min (34), lasting for 5 to 10 seconds, blood pressure crashes, which can cause myocardial ischemia. Before or after RVP, immediate use of vasoactive drugs to maintain blood pressure can help coronary blood flow restorated (32).

Anesthesia Selection

Anesthesia selection should be combined with many factors including basic diseases, patient's safety and comfort. General anesthesia can help control airway, keep sedation, ensure timely conversion to thoracotomy, but may increase airway complications, such as pulmonary infection. For patients with the poor general condition, this complication will greatly increase the risk of anesthesia (35).

Local anesthesia combined with sedation is another choice, which can be implemented with 4 mg/kg lidocaine subcutaneous infiltration, fentanyl, 0.025 to 0.2 ug/kg/min, and propofol, 2 to 5 mg/kg/h via vein pump. The target of sedation is 2-3 scores of Wilson sedation score (36), but this method can't allow us to implement TEE. Some doctors recommended thoracic epidural anesthesia, which can avoid intubation, and provide adequate postoperative analgesia. But postoperative low blood pressure can cause myocardial ischemia, and for the use of heparin, it can also lead thoracic epidural hematoma (37).

Anesthesia selections above have their advantages and limitations. There is no any guideline or expert consensus for us to select the best anesthetic way for the patients, which needs us to do further research (38).

This work was supported by a grant from the Department of Anesthesiology, West China Hospital, Sichuan University in China.
The authors declare no conflicts of interest.

References

1. Nishimura RA, Otto CM, Bonow RO, Carabello BA, Erwin JP 3rd, Guyton RA, et al. 2014 AHA/ACC Guideline for the Management of Patients With Valvular Heart Disease: A Report of the American College of Cardiology/American Heart Association Task Force on Practice Guidelines. *Circulation* 2014; 129 (23):e521-643.
2. Nkomo VT, Gardin JM, Skelton TN, Gottdiener JS, Scott CG, Enriquez-Sarano M, et al. Burden of valvular heart diseases: a population-based study. *Lancet* 2006;368(9540):1005-11.
3. Turina J, Hess O, Sepulcri F. Spontaneous course of aortic valve disease. *Eur Heart J* 1987;8(5):471-83.
4. Kelly TA, Rothbart RM, Cooper CM, Kaiser DL, Smucker ML, Gibson RS, et al. Comparison of outcome of asymptomatic to symptomatic patients older than 20 years of age with valvular aortic stenosis. *Am J Cardiol* 1988;61(1):123-30.
5. Leon MB, Smith CR, Mack M, Miller DC, Moses JW, Svensson LG, et al. Transcatheter aortic-valve implantation for aortic stenosis in patients who cannot undergo surgery. *N Engl J Med* 2010;363:1597-607.
6. Généreux P, Webb JG, Svensson LG, Kodali SK, Satler LF, Fearon WF, et al. Vascular complications after transcatheter aortic valve replacement: insights from the PARTNER (Placement of AoRTic TraNscathetER Valve) trial. *J Am Coll Cardiol* 2012; 60(12): 1043-52.
7. Toggweiler S, Leipsic J, Binder RK, Freeman M, Barbanti M, Heijmen RH, et al. Management of vascular access in transcatheter aortic valve replacement: part 1: basic anatomy, imaging, sheaths, wires, and access routes. *JACC Cardiovasc Interv* 2013, 6(7):643-53.
8. Hayashida K, Lefèvre T, Chevalier B, Hovasse T, Romano M, Garot P, et al. Transfemoral aortic valve implantation new criteria to predict vascular complications. *JACC Cardiovasc Interv* 2011;4(8):851-8.
9. Kahlert P, Al-Rashid F, Weber M, Wendt D, Heine T, Kottenberg E, et al. Vascular access site complications after percutaneous transfemoral aortic valve implantation. *Herz* 2009;34(5):398-408.
10. Alsac JM, Zegdi R, Blanchard D, Achouh P, Cholley B, Berrebi A, et al. Complications of the access during aortic valve implantation through transfemoral access. *Ann Vasc Surg* 2011;25(6):752-7.
11. Paolo P, Giuseppe F, Patrizia P. Rescue "valve in valve" implantation after late onset CoreValve cusp rupture leading to acute massive aortic insufficiency. *Catheter Cardiovasc Interv* 2014;83(7):E283-6.
12. Vallabhajosyula P, Bavaria JE. Transcatheter aortic valve implantation: complications and management. *J Heart Valve Dis* 2011;20(5):499-509.
13. Masson JB, Kovac J, Schuler G, Ye J, Cheung A, Kapadia S, et al. Transcatheter aoritic valve implantation: review of the nature, management, and avoidance of procedural complications. *JACC Cardiovasc Interv* 2009;2(9):811-20.
14. Liang M, Devlin G, Pasupati S. The incidence of transcatheter aortic valve implantation-related heart block in self-expandable medtronic corevalve and balloon-expandable edwards valves. *J Invasive Cardiol* 2012;24(4):173-6.
15. Hildick-Smith D, Redwood S, Mullen M, Thomas M, Kovac J, Brecker S, et al. Complications of transcatheter aortic valve implantation: avoidance and management. *EuroIntervention* 2011; 7(5):621-8.
16. Shannon J, Mussardo M, Latib A, Takagi K, Chieffo A, Montorfano M, et al. Recognition and management of complications during transcatheter aortic valve implantation. *Expert Rev Cardiovasc Ther* 2011;9(7):913-26.
17. Bleiziffer S, Ruge H, Hörer J, Hutter A, Geisbüsch S, Brockmann G, et al. Predictors for new-onset complete heart block after transcatheter aortic valve implantation. *JACC Cardiovasc Interv* 2010; 3 (5):524-30.
18. Seipelt RG, Hanekop GG, Schoendube FA, Schillinger W. Heart team approach for transcatheter aortic valve implantation procedures complicated by coronary artery occlusion. *Interact Cardiovasc Thorac Surg* 2012;14(4):431-3.
19. Ribeiro HB, Nombela-Franco L, Urena M, Mok M, Pasian S, Doyle D, et al. Coronary obstruction following transcatheter aortic valve implantation: a systematic review. *JACC Cardiovasc Interv* 2013; 6(5): 452-61.
20. Piazza N, Onuma Y, Jesserun E, Kint PP, Maugenest AM, Anderson RH, et al. Early and persistent intraventricular conduction abnormalities and requirements for pacemaking after percutaneous replacement of the aortic valve. *JACC Cardiovasc Interv* 2008;1(3):310-6.
21. Stabile E, Sorropago G, Cioppa A, Cota L, Agrusta M, Lucchetti V, et al. Acute left main obstructions following TAVI. *EuroIntervention* 2010;6(1):100-5.
22. Berry C, Cartier R, Bonan R. Fatal ischemic stroke related to non permissive peripheral artery access for percutaneous aortic valve replacement. *Catheter Cardiovasc Interv* 2007;69(1):56-63.
23. Walther T, Falk V, Kempfert J, Borger MA, Fassl J, Chu MW, et al. Transapical minimally invasive aortic valve implantation: the initial 50 patients. *Eur J Cardiothorac Surg* 2008;33(6):983-8.
24. Tarantini G, Gasparetto V, Napodano M, Fraccaro C, Gerosa G, Isabella G. Valvular leak aftertranscatheter aortic valve implanation: a clinician update on epidemiology, pathophysiology and clinical implications. *Am J Cardiovasc Dis* 2011;1(3):312-20.
25. Nuis RJ, Van Mieghem NM, Tzikas A, Piazza N, Otten AM, Cheng J, et al. Frequency, determinants, and prognostic effects of acute kidney injury and red blood cell transfusion in patients undergoing transeatheter aortic valve implantation. *Catheter Cardiovasc Interv* 2011;77(6):881-9.
26. Bagur R, Webb JG, Nietlispach F, Dumont E, De Larochellière R, Doyle D, et al. Acute kidney injury following transcatheter aortic valve implantation: predictive factors, prognostic value, and comparison with surgical aortic valve replacement. *Eur Heart J* 2010;31(7):865-74.
27. Svensson LG, Dewey T, Kapadia S, Roselli EE, Stewart A, Williams M, et al. United States feasibility study of transeatheter insertion of a stented aortic valve by the left ventficular apex. *Ann Thorac Surg* 2008;86(1):46-54.
28. Dashkevich A, Blanke P, Siepe M, Pache G, Langer M, Schlensak C. Preoperative assessment of aortic annulus dimensions: comparison of noninvasive and intraoperative measurement. *Ann Thorac Surg* 2011;91(3):709-14.
29. Babaliaros VC, Liff D, Chen EP, Rogers JH, Brown RA, Thourani VH, et al. Can balloon aortic valvuloplasty help determine appropriate transcatheter aortic valve size? *JACC Cardiovasc Interv* 2008; 1 (5):580-6.
30. Zamorano JL, Badano LP, Bruce C, Chan KL, Gonçalves A, Hahn RT, et al. EAE/ASE recommendations for the use of echocardiography in new transcatheter interventions for valvular heart disease. *Eur Heart J* 2011;32(17):2189-214.
31. Covello RD, Ruggeri L, Landoni G, Guarracino F, Bignami E, Gonfalini M, et al. Transcatheter implantation of an aortic valve: anesthesiological management. *Minerva Anestesiol* 2010;76(2):100-8.
32. Franco A, Gerli C, Ruggeri L, Monaco F. Anesthetic management of transcatheter aortic valve implantation. *Ann Card Anaesth* 2012;15(1):54-63.
33. Christ M, Sharkova Y, Geldner G, Maisch B. Preoperative and perioperative care for patients with suspected or established aortic stenosis facing noncardiac surgery. *Chest* 2005;128(4):2944-53.
34. Webb JG, Pasupati S, Achtem L, Thompson CR. Rapid pacing to facilitate transcatheter prosthetic heart valve implantation. *Catheter Cardiovasc Interv* 2006;68(2):199-204.
35. Aitkenhead AR. Injuries associated with anaesthesia. A global perspective. *Br J Anaesth* 2005;95(1):95-109.
36. Behan M, Haworth P, Hutchinson N, Trivedi U, Laborde JC, Hildick-Smith D. Percutaneous aortic valve implants under sedation: our initial experience. *Catheter Cardiovasc Interv* 2008;72(7):1012-5.
37. Mukherjee C, Walther T, Borger MA, Kempfert J, Schuler G, Mohr FW, et al. Awake transapical aortic valve implantation using thoracic epidural anesthesia. *Ann Thorac Surg* 2009;88(3):992-4.
38. Ruggeri L, Gerli C, Franco A, Barile L, Magnano di San Lio MS, Villari N, et al. Anesthetic management for percutaneous aortic valve implantation: an overview of worldwide experiences. *HSR Proc Intensive Care Cardiovasc Anesth* 2012;4(1):40-6.